


Hemorrhagic stroke as a serious complication of scorpion: envenomation Systematic review with an exemplary case description

Yaşar Barış Turgut¹, Tumay Cakir²

¹Internal Medicine Clinic, Aydın State Hospital, Efeler, Aydın, Turkey

² Intensive Care Clinic, Muğla Training and Research Hospital, Menteşe, Muğla, Turkey”



Date of submission: 6th September 2024

Date of Acceptance: 20th February 2025

Date of publication: 15th March 2025

Abstract

Introduction: Scorpion envenomations are toxicological emergencies with serious central nervous system complications including intracranial hemorrhage (ICH). The aim of this study is to review the reported cases of ICH as a complication of scorpion envenomation, with a description of an exemplary case of subarachnoid hemorrhage.

Material & Methods: A systematic search was performed according to Preferred Reporting Items for Systematic Review and Meta-Analyses (PRISMA) guidelines. Data regarding demographics, clinical presentation, causative species of the scorpion, treatments, and outcomes were collected.

Results: Fifteen reports documenting 16 cases were included in our review, evaluating demographical features and outcomes of the cases of ICH from scorpion envenomations. Reported cases were from tropical and subtropical regions, primarily from India followed by Turkey and most frequently in young adult male individuals. Of the 8 reported cases with sufficient information for analysis, 4 were caused by *M. tamulus*, while *N. Hierochonticus*, *L. Quinquestriatus*, *P. Swannerdani* and *T. Trivittatus* were each in 1 case. Out of 14 cases with follow-up information, 12 cases involved ICH involving the basal nuclei or cerebral lobes and only 2 cases had subarachnoid hemorrhage; all cases except one were treated conservatively with outcomes including 7 complete recovery, 5 death whereas 2 were ambulatory.

Conclusion: Hemorrhagic stroke as a complication of scorpion envenomation is a life-threatening emergency where early diagnosis and prompt management are critical.

Keywords: Acute cerebrovascular accident . Intracranial hemorrhage . Scorpion envonemation. Subarachnoid hemorrhage . Systematic review . Toxicology

Introduction

Scorpion envonemation, a major public health problem, is a potentially life-threatening emergency in various regions of the third world including India, Turkey, Africa, and Latin American countries¹⁻¹⁹. Taxonomically, the most common species for envenomation is the Indian red scorpion

(*Mesobuthus tamulus*), which is known as the world's deadliest scorpion, encountered in India, Pakistan, Nepal, and Sri Lanka^{8-10,12-14,16-18,20}. Envenoming caused by the Brazilian yellow scorpion (*Tityus trivittatus*) is an important public health problem in Central and South American countries^{11,17,21}. The most common other species of scorpion are *Nebo hierochonticus*, *Leiurus quinquestriatus*, *Palamneus swammerdami* in different areas of the world^{7,18,22}. In Turkey the most common species of scorpion is *Mesobuthus* spp. and scorpion stings are a common health problem, especially in hot climates.

Clinically, systemic effects of scorpion envenomation such as tachycardia, hypertension, hyperglycemia, hyperthermia, pulmonary edema, and tachypnea are caused by involvement of the sympathetic nervous system^{2,22,23}. As a result of involvement of the parasympathetic system, various clinical findings such as bradycardia, hypotension, and bronchoconstriction may occur among patients with a scorpion bite, but involvement of the cerebrovascular system should be considered in the presence of a decrease in sensorium, neurological deficit, or seizure^{7,9}. Radiological studies such as computed tomography (CT) and magnetic resonance imaging (MRI) are adequate to confirm the diagnosis of neurological involvement in these patients¹⁵. Neurological complications following scorpion envonemations are rarely reported and most of these cases are in the form of ischemic stroke resulting in infarction, but intracranial hemorrhage (ICH), called “hemorrhagic stroke”, is

Access this article online

Website: <https://www.nepjol.info/index.php/NJN>

DOI: <https://10.3126/njn.v21i4.69564>

HOW TO CITE

Turgut YB, Cakir T. Hemorrhagic stroke as a serious complication of scorpion sting: Systematic review with an exemplary case description. NJNS. 2024;24(4):3-7



Address for correspondence:

Yaşar Barış Turgut

Internal Medicine Clinic, Aydın State Hospital, 09100 Efeler, Aydın, Turkey.

E-mail: barroturgut@yahoo.com

Copyright © 2023 Nepalese Society of Neurosurgeons (NESON)

ISSN: 1813-1948 (Print), 1813-1956 (Online)



This work is licensed under a Creative Commons Attribution-Non Commercial 4.0 International License.

an extremely rare but life-threatening event^{17,23}. The aim of this systematic review is to assess the demographical features, localization of the hemorrhage, and the outcome of the cases, in addition to the species of scorpion causing envenomation in an attempt to direct future workup and management of the scorpion envenomations complicated with ICH and to present our clinical experience with an extremely rare case of subarachnoid hemorrhage (SAH) due to scorpion sting poisoning.

Material & Methods

Literature search

The systematic review was conducted following the current version of PRISMA (Preferred Reporting Items for Systematic Reviews and Meta-Analyses) guidelines²⁴. In order to reduce possible publication bias and enhance the quality of the analysis, certain inclusion and exclusion criteria were set arbitrarily, institutional review board approval was not required for this study.

Relevant databases such as PubMed, Google Scholar, and Web of Science were searched by performing a keyword search using “acute cerebrovascular accident”, “brain”, “hemorrhage”, “intracranial hemorrhage”, “scorpion sting” and “subarachnoid hemorrhage” for case studies and case reports published from January 1990 to July 2023. Eligibility criteria

In this systematic review, studies including adult and pediatric patients available in the English language were included for review. This study is limited to cases that resulted in the “hemorrhagic stroke” (intraparenchymal hemorrhage, SAH, subdural or intraventricular hemorrhage) as a complication of scorpion envenomation. Information regarding demographics, clinical presentation, causative species of the scorpion, treatments (conservative or surgical), and follow-up results were collected from each study. Publications of patients with encephalopathy or ischemic stroke of the central nervous system (CNS) resulting in infarction or hemorrhagic infarction were excluded. As a rule, other complications (cardiovascular, pulmonary, neuromuscular or renal compromise) associated with scorpion envenoming are excluded from the scope of this study.

Data extraction

Studies were reviewed by the authors of the article individually and then they underwent a second review if there was any disagreement between the authors. A PRISMA flowchart further demonstrating the inclusion in this report is included in Figure 1.

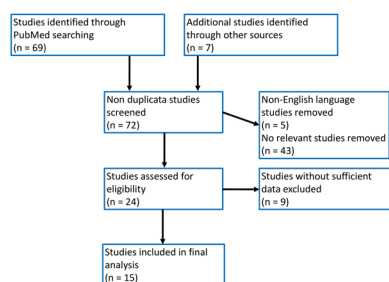


Figure 1: A PRISMA diagram of study identification and selection reporting a final inclusion of 15 studies in this review. PRISMA, Preferred Reporting items for Systematic Review

Results

Literature review

From January 1990 to July 2023, a total of 15 publications with 16 cases were identified describing case reports (n=14) or case series (n=1) of scorpion envenomations complicated with hemorrhagic stroke. Of the 15 publications reporting scorpion envenomations complicated with ICH, 14 full-text English papers and the remaining single web address were reviewed. The distribution of the publications according to their country of origin was as follows: The five countries that contributed articles were India (n=10), Turkey (n=2), Argentina (n=1), Nigeria (n=1), and Saudi Arabia (n=1). In all cases with scorpion envenomation, the definitive diagnosis was based on a history of a scorpion sting, with the scorpion being observed or killed by relatives of the patients. However, species of the scorpion were identified in 8 (50% of cases) with *M. tamulus* (n=4), *N. hierochonticus* (n=1), *L. quinquestratus* (n=1), *P. swammerdami* (n=1), *T. trivittatus* (n=1), while the remaining 8 cases were without enough data (n=6) or were unknown (n=2). The median age and mean age were 25 years and 33.1 years, respectively, with a range of 8 months-83 years of age. Of the 12 patients with data available, gender was 66.6% male and 33.4% female. Except for a case where sufficient data is not available, all patients with scorpion envenomations complicated by hemorrhagic stroke were admitted to the hospital within 48 hours of the scorpion sting. Out of 14 cases with data available, however, a total of 11 (78.6%) adult patients with scorpion envenomations were complicated by hemorrhagic stroke, while only the remaining three (21.4%) pediatric patients were complicated by hemorrhagic stroke. Except for 3 cases without data available, all cases reported had CT (n=8), MRI (n=2), and CT plus MRI (n=3) findings consistent with ICH. In 15 cases of hemorrhagic stroke with multiple areas of involvement, the localizations of the hemorrhage were in the basal nuclei (n=7), cerebral lobes (frontal, parietal, or occipital) (n=5), lateral ventricle (n=3), cerebellum (n=2), thalamus (n=1), subdural space (n=1) and subarachnoid space (n=2). Out of 15 cases with data available, the vast majority of patients with hemorrhagic stroke were treated with a conservative approach that included prazosin and various supportive measures (n=11), while only one underwent surgical intervention for removal of the ICH. Follow-up imaging was available in 14 (87.5% of cases), that recovered completely (n=7) or were ambulatory (n=2), while 5 (38.5%) died within 4-5 days after admission to the hospital. A summary of the cases reported in the current literature is given in Table 1 (http://www.japi.org/april_2009/article_12.html) 1,3,6,8,10,12-16,18-20,25.

Exemplary case description

A 62-year-old man was admitted to the regional emergency department after a scorpion sting and 1 mL scorpion anti-venom (Scorpion Anti-venom, Albila Serum Biyolojik Ürünler San. ve Tic. A.Ş., Republic of Turkey Public Health General Directorate, Turkey) was given intravenously. On admission, he complained of chills, sweating, nausea, and vomiting, but his physical and neurological examinations were normal. Laboratory tests including myoglobin were 354.2 ng/mL (N= 28-72 ng/mL), mass Ck-Mb 14.46 ng/mL (N= 0-4.94 ng/mL), and troponin-T

678.6 pg/mL (N= 0-14 pg/mL) initially, but increased to 892.7 pg/mL on the same day and then decreased to 77.3 pg/mL at follow-up. On the 6th day, he developed a headache and stiff neck, suggesting the suspicion of SAH, and a lumbar puncture disclosed hemorrhagic cerebrospinal fluid. Then, nimodipine treatment was started because susceptibility-weighted imaging (SWI) and fluid-attenuated inversion recovery (FLAIR) sequences of MRI of the brain revealed few multiple microhemorrhage foci in the gray matter of both posterior parietal lobes, compatible with SAH (Figure 2).

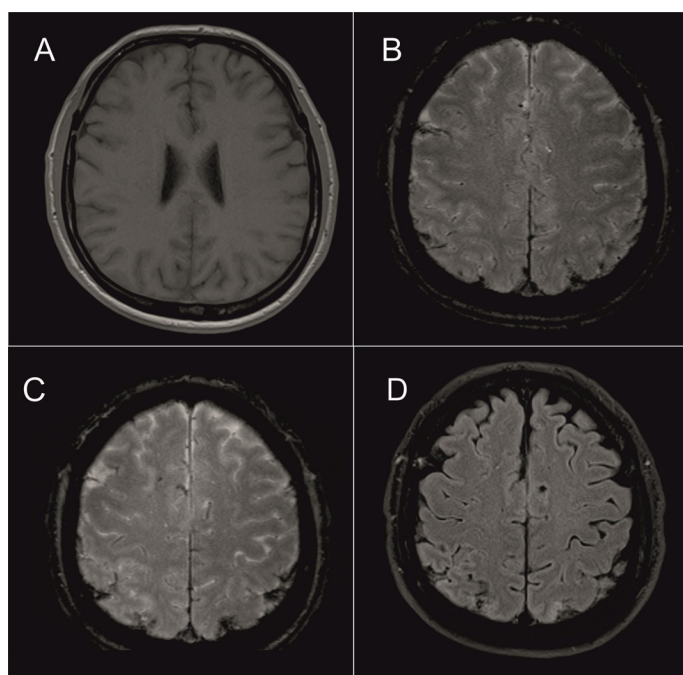


Figure 2: Axial of T1-weighted (A) and T2-weighted (B) images are essentially normal, but axial susceptibility-weighted imaging (SWI) (C) and fluid-attenuated inversion recovery (FLAIR) (D) sequences show few multiple microhemorrhage foci in the gray matter of both posterior parietal lobes, suggestive of subarachnoid hemorrhage (SAH)

Three weeks later, the patient was discharged without sequelae. The detailed clinical history of the patient was previously presented in detail in another source ²⁵.

Discussion

To our knowledge, this is the first reported systematic review of the clinical characteristics of cases with hemorrhagic stroke from scorpion envenomation, using PRISMA guidelines.

Scorpions live in many countries, mainly in underdeveloped countries of tropical and subtropical regions, but are found in developed countries where the weather is hot and rainy, more frequent in summer ^{4,5,26}. Nearly 1500 scorpion species have been identified in the world and many scorpion species are harmless, but it is also known in the possible scorpion species that was responsible for the exemplary case reported from the Muğla region in Southwestern Anatolia in Turkey (Figure 3).

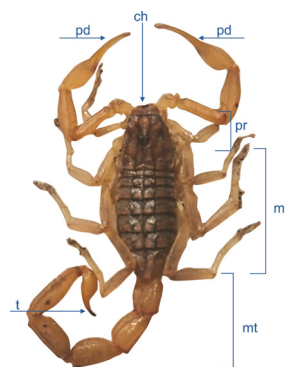


Figure 3: Drawing of basic scorpion morphological structure consisting of three parts: metasoma (tail); mesosoma (abdomen); and prosoma (head). Note that the poison sting is located at the metasoma of the scorpion. pd, pedipalp (pinchers); ch, chelicerae (mandibles); pr, prosoma (head); ms, mesosoma (abdomen); mt, metasoma (tail); t, telson (venom apperatus)

It has been reported that the venom, consisting of polypeptides with pro-inflammatory properties, is produced in the glands located in the scorpion's tail, called “telson”, and causes the release of inflammatory cytokines like interleukin (IL)-1 β , IL-6, IL-8 and tumor necrosis factor (TNF)-alpha ^{9,22,27}. Scorpion envenomation can affect individuals of all ages, although it usually occurs in young males as a natural result of them being more active and mobile in daily life ^{4,5,9,11,17}. Clinically, complications of scorpion envenoming are variable extending from mild ones to more serious ones (hypertension, myocarditis, cardiac arrhythmias, cardiogenic shock, heart failure, brochospasm, pulmonary edema, respiratory failure) with damage to the cardiac, pulmonary, renal, coagulation cascade, and CNS ^{21,28}. Among these complications, cerebrovascular involvement, hemorrhagic or ischemic, occurs in about 2-10% of cases with scorpion envenomation as the result of direct cardiac toxicity of the venom or due to the release of catecholamines into the bloodstream ^{1,3,6,7,9,12,14,18-21,23,29}. In a Tunisian study with 951 cases of severe scorpion envenomation, about 80% of the cases had neurological manifestations⁴, whereas cerebrovascular complications were seen in only 10% of patients from India, particularly in those with the sting of *M. tamulus* (Indian red scorpion) and *T. Serrulatus* ^{6,19,21,23,29}. It has been suggested that hemorrhagic stroke occurs in the setting of acute increase in arterial blood pressure related to sympathetic overstimulation, while ischemic stroke is a result of cerebral embolism or hypoperfusion, consumption coagulopathy, or vasculitis ^{18,21,23}.

In an analysis made through scientific databases up to 2013, a total of 23 cases with cerebral involvement were identified and two-thirds of these were compiled as ischemic stroke where only one-third had ICH and among the hemorrhagic strokes, SAH was encountered in only one case ^{14,19,29}. To the best of our knowledge, the present exemplary case is the second reported case of SAH as a serious complication of a scorpion sting in the literature ²⁵. ICHs in victims of scorpion stings were localized to the basal ganglia in four cases, the cerebral lobes in two cases, the ventricular system in one case, and the remaining case had multiple ICH foci, possibly due to an increased arterial blood pressure as part of the “autonomous storm” (Table 1) ^{1,3,6,8,10,12-16,18-20,25}.

Table 1: Summary of cases with intracranial hemorrhage (ICH) following scorpion sting reported in 16 cases in the English literature between 1990 and 2023, including the current demonstrative case

Author [ref.#]	Year	Country	Age/Sex	Species of Scorpion	Imaging	Localization of Hemorrhage	Treatment	Outcome
Rai et al. ¹⁶	1990	India	25 yrs/M	Unknown	CT	Caudate nucleus, lateral ventricle	Conservative	Alive, recovery
Annobil et al. ¹	1991	Saudi Arabia	3 yrs/M	N. hiero- chonticus	CT	Multiple cerebral and cerebellar	Conservative	Alive, recovery
Gambhir et al. ¹⁴	1998	India	12 yrs/F	P. swannerd- ani	CT	Lobar, basal ganglia	Conservative	Alive, recovery
Kishore*	2008	India	18 yrs/M	M. tamulus	NS	Lobar, multiple	NS	Alive
Sarkar et al. ¹⁸	2008	India	Adult/NS	NS	CT/MRI	Putamen	Conservative	Alive, recovery
			Adult/NS	NS	CT/MRI	Lateral ventricle	Conservative	Died (5 dys)
Mathur et al. ¹⁴	2010	India	NS	NS	NS	Subarachnoid	NS	NS
Dube et al. ²⁰	2011	India	NS	NS	NS	NS	NS	Died
Eze et al. ⁶	2014	Nigeria	83 yrs/F	NS	CT	Lobar	Conservative	Alive with sequela
Kumar et al. ¹²	2014	India	25 yrs/M	M. tamulus	MRI	Thalamus, cerebellum	Conservative	Died (NS)
Sığırcı et al. ¹⁹	2014	Turkey	8 mos/F	L. quinquies- triatus	MRI	Bilateral subdural	Conservative	Alive with sequela
Bordon et al. ³	2018	Argentina	69 yrs/F	T. trivittatus	CT	Lobar, basal ganglia	Surgery	Died
Mishra et al. ¹⁵	2018	India	29 yrs/M	NS	CT	Basal ganglia	NS	NS
Majumdaret al. ¹³	2020	India	40 yrs/M	M. tamulus	CT	Basal ganglia, lateral ventricle	Conservative	Died (4 days)
Gowtham et al. ¹⁰	2022	India	31 yrs/M	M. tamulus	CT	Basal ganglia	Conservative	Alive, recovery
Uysal et al. ²⁵	2023	Turkey	62 yrs/M	Unknown	CT/MRI	Subarachnoid	Conservative	Alive, recovery

Abbreviations: M, male; F, female; dys, days; mos, months; yrs, years; L, Leiurus; M, Mesobuthus; N, Nebo; P, Palamnaes; T, Tityus; CT, computed tomography; MRI, magnetic resonance imaging; NS, not stated.

* http://www.japi.org/april_2009/article_12.html

Even today, the underlying pathophysiological mechanisms of injury remain unclear. In a report from Thailand, Wiwanitkit suggested that neurological complications of scorpion stings are the result of anaphylaxis and acute renal failure, and not the direct effect of toxin on the brain tissue²³. Nevertheless, many authors have suggested that possible deleterious mechanisms of complications of scorpion envenoming include hypoperfusion related to cardiac embolism and arrhythmias, hypertensive attack following “autonomic storm”, cerebral vasospasm, inflammation, direct toxicity, dysfunction of the endothelium, thrombosis, coagulopathy, and disseminated intravascular coagulation^{12,18,28}. Amongst these, an acute rise in the arterial blood pressure related to sympathetic overstimulation, called “autonomic storm”, which may rupture unprotected or diseased perforating arteries of the brain, has been suggested for the development of hemorrhagic strokes in patients with scorpion envenomation^{2,29}. Theoretically, it has been reported that scorpion neurotoxins cause opening of voltage-gated

Na⁺ (“β-toxins”) channels or inhibition of the deactivation of excitatory Na⁺ s (“α-toxins”) and inhibitory K⁺ ion channels (“charybdotoxins”). This process causes the release of large amounts of sympathetic and parasympathetic mediators for catecholamine and acetylcholine, respectively, as a result of depolarization at the level of postsynaptic postganglionic nerve terminals of the autonomic nervous system (ANS)^{9,12,27,30-35}. Furthermore, inflammatory cytokines such as neuropeptide Y, IL-1, TNF-α, and endothelin also cause damage to the vascular endothelium, called toxin-induced vasculitis^{9,22}. In addition to affecting the coagulation cascade, known as “disseminated intravascular coagulation” (DIC), ICH may occur as a result of endothelial damage and increased catecholaminergic activity³. Clinically, clinical manifestations may develop after a scorpion sting: (1) encephalopathy caused by the effects of neurotoxin on the CNS; (2) blood pressure fluctuations related to the counter-effects of the sympathetic and parasympathetic systems; (3) vasculitis and thrombosis of the vessels with infarction as a

result of damage to the endothelium by toxins; (4) ischemic or hemorrhagic stroke due to DIC; and (5) various neurologic manifestations that result from prolonged hypoxia, anoxia, vasospasm or vasoconstriction, and dehydration^{7,18,23,29,36,37}. As occurred in the exemplary case description, imaging studies such as CT and/or MRI, including SWI and FLAIR sequences, are useful to confirm the hemorrhagic complications such as ICH, SAH, or subdural hematoma and/or the ischemic complications that include cerebral infarct as a consequence of the scorpion sting.

Management of scorpion envenoming, including conservative approaches such symptomatic treatment, support of vital functions, and specific treatment (anti-scorpion venom), consist of the alpha-blocker prazosin for reversal of the overstimulation of peripheral alpha 1-adrenergic receptors, anti-scorpion venom, and supportive measures in the form of blood products, nimodipine, mannitol, etc. that reduce the risk of cardiopulmonary complications as well as the morbidity and mortality of cerebral stroke that is either hemorrhagic or ischemic^{28,29}. Recently, however, it has been suggested that the antivenom against scorpion intoxication only blocks the toxin in the bloodstream, but not at the nerve terminals of the CNS where binding to specific receptors is suspected^{9,22}. As seen in Table 1, in some cases of hemorrhagic stroke due to scorpion sting, in addition to the conservative treatment approach, various surgical treatment options such as burr-hole or craniotomy procedure are applied for the drainage of bleeding with intraparenchymal, subdural or intraventricular localization^{1,3,6,8,10,12-16,18-20,25}. Despite various treatments for scorpion envenomation, both morbidity and mortality rates still remain high, especially in complicated cases of hemorrhagic stroke caused by the scorpion species such as *M. tamulus* and *T. trivittatus*, and new prospective studies are required in the future to improve their outcome.

Our systematic review has several limitations. First, it was difficult to perform a systematic review because of the limited and heterogeneous nature of the data available, such as clinical symptoms and signs, drugs administered to the patients, and outcomes (duration of follow-up, etc.). In addition, this retrospective literature review was associated with publication bias since it included only those cases of hemorrhagic stroke from scorpion stings reported in English-language journals indexed by scientific databases, although there are many published cases in languages other than English.

Conclusion

In conclusion, it is important to report this case because the CNS damage from scorpion sting poisoning may occur as a life-threatening condition and it should be considered in the differential diagnosis when confronting a patient with hemorrhagic stroke in the emergency service in endemic regions of the world for toxic scorpion species. Early recognition together with appropriate treatment with prazosin and other supportive measures, in addition to anti-scorpion venom administration, can reduce the mortality and morbidity in cases of scorpion sting poisoning with involvement of CNS, despite the associated very poor patient prognosis.

Acknowledgements The English text of this paper has been revised by Professor Walter A. Hall from Department of Neurosurgery, SUNY Upstate University Hospital, Syracuse, New York, United States. We thank the anonymous reviewers of the journal Nepal Journal of Neuroscience for their constructive comments and help with the manuscript.

Author contributions Yaşar Barış Turgut write-up of article, data acquisition, analysis, reviewing literature, conceptualization, final review, and submission. Tümay Çakır conceptualization, supervision, and final review before submission. The author (s) read and approved the final manuscript.

Funding This research received no external funding.

Data availability The data supporting this systematic review were derived from previously published studies, which have been duly cited.

Declarations

Conflict of interest Not applicable.

Ethical approval Not applicable.

Informed consent Not applicable

References

1. Annobil SH, Omojola MF, Vijayakumar E. Intracranial haemorrhages after Nebo hierochonticus scorpion sting. *Ann Trop Paediatr*. 1991;11(4):377-80. doi: 10.1080/02724936.1991.11747533.
2. Bahloul M, Chabchoub I, Chaari A, Chtara K, Kallel H, Dammak H, Ksibi H, Chelly H, Rekik N, Ben Hamida C, Bouaziz M. Scorpion envenomation among children: clinical manifestations and outcome (analysis of 685 cases). *Am J Trop Med Hyg*. 2010 v;83(5):1084-92. doi: 10.4269/ajtmh.2010.10-0036.
3. Bordón L, Paredes W, Pacheco R, Graneros N, Tolosa C, Galarza G, Godoy DA. Intracerebral hemorrhage secondary to scorpion toxin in the Northwest of Argentina; a case report. *Bull Emerg Trauma*. 2018;6(3):253-256. doi: 10.29252/beat-060312.
4. Bouaziz M, Bahloul M, Kallel H, Samet M, Ksibi H, Dammak H, Ahmed MN, Chtara K, Chelly H, Hamida CB, Rekik N. Epidemiological, clinical characteristics and outcome of severe scorpion envenomation in South Tunisia: multivariate analysis of 951 cases. *Toxicon*. 2008;52(8):918-26. doi: 10.1016/j.toxicon.2008.09.004.
5. Chippaux JP, Goyffon M. Epidemiology of scorpionism: a global appraisal. *Acta Trop*. 2008;107(2):71-9. doi: 10.1016/j.actatropica.2008.05.021.
6. Eze CO, Onwuekwe I, Ekenze O. Stroke as a rare consequence of scorpion sting and scorpion ingestion: a case report from South East Nigeria. *Ann Trop Med Public Health*. 2014;7(4):202-205. doi:10.4103/1755-6783.150114.
7. Gadwalkar SR, Bushan S, Pramod K, Gouda C, Kumar PM. Bilateral cerebellar infarction: a rare complication of

- scorpion sting. *J Assoc Physicians India*. 2006;54:581-3. PMID: 17089911.
8. Gambhir IS, Singh DS, Pattnaik DN. Stroke in a young woman. *Postgrad Med J*. 1998;74(875):555-6. doi: 10.1136/pgmj.74.875.555.
9. Godoy DA, Badenes R, Seifi S, Salehi S, Seifi A. Neurological and systemic manifestations of severe scorpion envenomation. *Cureus*. 2021;13(4):e14715. doi: 10.7759/cureus.14715.
10. Gowtham H, Jagadeesan M, Prasanna Karthik S, Kannan R, Gowrisankar A. Scorpion sting bite with intracerebral bleed: a case report. *Int J Adv Med*. 2022;9(2):187-189. doi: <https://doi.org/10.18203/2349-3933.ijam20220134>.
11. Guerra-Duarte C, Saavedra-Langer R, Matavel A, Oliveira-Mendes BBR, Chavez-Olortegui C, Paiva ALB. Scorpion envenomation in Brazil: current scenario and perspectives for containing an increasing health problem. *PLoS Negl Trop Dis*. 2023;17(2):e0011069. doi: 10.1371/journal.pntd.0011069.
12. Kumar TP, Reddy VU, Narayan PD, Agrawal A. Symmetrical thalamic and cerebellar hemorrhages following scorpion envenomation. *Int J Stud Res*. 2014;4(1):15-17. doi:10.4103/2230-7095.137616.
13. Majumdar A, Atam V, Ansari SA, Kumar S, Bhardwaj A. Basal ganglia hemorrhage secondary to scorpion sting: a fatal presentation. *Egypt J Neurol Psychiatry Neurosurg*. 2020;56:65. <https://doi.org/10.1186/s41983-020-00198-9>.
14. Mathur S, Jain S, Dubey T, Kulshrestha M, Mathur S, Jangid R, Ram Ch. Scorpion sting presenting as subarachnoid hemorrhage in an elderly male. *J Indian Academy of Geriatrics*. 2010;6:171-172.
15. Mishra A, Binu A, Abraham G, Vanjare H, George T, Iyadurai R. Cerebrovascular injury following scorpion sting and snake envenomation: a case series. *Can J Neurol Sci*. 2018;45(6):669-674. doi: 10.1017/cjn.2018.328.
16. Rai M, Shukla RC, Varma DN, Bajpai HS, Gupta SK. Intracerebral hemorrhage following scorpion bite. *Neurology*. 1990;40(11):1801. doi: 10.1212/wnl.40.11.1801.
17. Santos MS, Silva CG, Neto BS, Grangeiro Júnior CR, Lopes VH, Teixeira Júnior AG, Bezerra DA, Luna JV, Cordeiro JB, Júnior JG, Lima MA. Clinical and epidemiological aspects of scorpionism in the world: a systematic Review. *Wilderness Environ Med*. 2016;27(4):504-518. doi: 10.1016/j.wem.2016.08.003.
18. Sarkar S, Bhattacharya P, Paswan A. Cerebrovascular manifestations and alteration of coagulation profile in scorpion sting: a case series. *Indian J Crit Care Med*. 2008;12(1):15-7. doi: 10.4103/0972-5229.40944.
19. Sığircı A, Öztürk M, Yakıncı C. Cerebral atrophy and subdural haemorrhage after cerebellar and cerebral infarcts in an 8-month-old child after having been stung by a scorpion. *BMJ Case Rep*. 2014;2014:bcr2014205091. doi: 10.1136/bcr-2014-205091.
20. Dube S, Sharma VK, Dubey TN, Gouda NB, Shrivastava V. Fatal intracerebral haemorrhage following scorpion sting. *J Indian Med Assoc*. 2011;109(3):194-5. PMID: 22010593.
21. Del Brutto OH. Neurological effects of venomous bites and stings: snakes, spiders, and scorpions. *Handb Clin Neurol*. 2013;114:349-68. doi: 10.1016/B978-0-444-53490-3.00028-5.
22. Abroug F, Ouanes-Besbes L, Tilouche N, Elatrous S. Scorpion envenomation: state of the art. *Intensive Care Med*. 2020;46(3):401-410. doi: 10.1007/s00134-020-05924-8.
23. Wiwanitkit V. Scorpion sting and cerebrovascular complication. *Int J Stroke*. 2013;8(8):E58. doi: 10.1111/ijss.12176.
24. Moher D, Liberati A, Tetzlaff J, Altman DG; PRISMA Group. Preferred reporting items for systematic reviews and meta-analyses: the PRISMA statement. *PLoS Med*. 2009;6(7):e1000097. doi: 10.1371/journal.pmed.1000097.
25. Uysal AI, Özdemir I, Akçadağ T, Gürsoy M, Turgut YB, Çakır T. Subarachnoid hemorrhage following scorpion bite: a case report. *EJM*. 2023;62 (4):576-578. <https://doi.org/10.19161/etd.1289701>.
26. Souza DG, Tanaka K, Algemi W, Dezena RA, Borges MM, Pereira CU, Lima AA, Feitosa SC. Hemorrhagic stroke following scorpion sting. a case report. *Rev Chil Neurocir*. 2013;39:69-70. <https://api.semanticscholar.org/CorpusID:74844805>.
27. Petricevich VL. Scorpion venom and the inflammatory response. *Mediators Inflamm*. 2010;2010:903295. doi: 10.1155/2010/903295.
28. Godoy DA, Badenes R, Seifi S, Salehi S, Seifi A. Neurological and systemic manifestations of severe scorpion envenomation. *Cureus*. 2021;13(4):e14715. doi: 10.7759/cureus.14715.
29. Del Brutto OH, Del Brutto VJ. Scorpion stings: focus on cerebrovascular complications of envenoming. *Int J Stroke*. 2013;8(4):E8. doi: 10.1111/j.1747-4949.2012.00940.x.
30. Bergeron ZL, Bingham JP. Scorpion toxins specific for potassium (K⁺) channels: a historical overview of peptide bioengineering. *Toxins (Basel)*. 2012;4(11):1082-119. doi: 10.3390/toxins4111082.
31. Couraud F, Jover E, Dubois JM, Rochat H. Two types of scorpion receptor sites, one related to the activation, the other to the inactivation of the action potential sodium channel. *Toxicon*. 1982;20(1):9-16. doi: 10.1016/0041-0101(82)90138-6.
32. Jover E, Bablito J, Couraud F. Binding of beta-scorpion toxin: a physicochemical study. *Biochemistry*. 1984;23(6):1147-52. doi: 10.1021/bi00301a018.
33. Ludolph AC, Spencer PS. Scorpion toxins (alpha and beta). In: Spencer PS, Schaumburg HH, eds. *Experimental and Clinical Neurotoxicity*. Oxford, England:Oxford University Press; 2000. <https://doi.org/10.1093/oso/9780195084771.001.0001>.
34. Possani LD, Becerril B, Delepierre M, Tytgat J. Scorpion toxins specific for Na⁺-channels. *Eur J Biochem*. 1999;264(2):287-300. doi: 10.1046/j.1432-1327.1999.00625.x.
35. Thomas VV, George T, Mishra AK, Mannam P, Ramya I. Lateral medullary syndrome after a scorpion sting. *J Family Med Prim Care*. 2017;6(1):155-157. doi: 10.4103/2249-4863.214988.
36. Romero NO, Hernández TJ. Cerebral edema associated to scorpion sting: a two case sting report. *J Venom Anim Toxins Incl Trop Dis*. 2005;11(4):594-600. doi:10.1590/S1678-91992005000400015.
37. Thacker AK, Lal R, Misra M. Scorpion bite and multiple cerebral infarcts. *Neurol India*. 2002;50(1):100-2. PMID: 11960164.