

# Conservative management of periapical cysts – A case series



Devakumari Shanmugam<sup>1</sup>, Vijhayapriya Thanasekaran<sup>2</sup>, Nandini Biradar<sup>3</sup>, Bhavanirekha Natarajan<sup>4</sup> and Neil Dominic<sup>5</sup>

<sup>1</sup>Associate Professor and Head, <sup>2</sup>Senior Resident, Department of Dentistry, Indira Gandhi Medical College and Research Institute (Government), Puducherry-605008, India, <sup>3</sup>Associate Professor, Department of Ophthalmology, Indira Gandhi Medical College and Research Institute (Government), Puducherry-605008, India, <sup>4</sup>Associate Professor, Department of Dentistry, Bidar institute of Medical Sciences, Bidar, Karnataka-585401, <sup>5</sup>Assistant Professor, Department of Dentistry, Government Rajaji hospital, Madurai Medical college, Madurai, Tamilnadu

Submission: 05-01-2021

Revision: 27-04-2021

Publication: 01-06-2021

## ABSTRACT

Non vital teeth with periapical cysts do not respond to routine root canal therapy alone. Conventional RCT (root canal therapy) should be combined with conservative management of cysts or surgical management. Contemporary options for non-surgical management are repeated intra canal dressing with Ca (OH)<sub>2</sub>, aspiration and decompression techniques. Repeated intra canal dressing with Ca(OH)<sub>2</sub> and Iodoform (Metapex) was advocated in 15 of our patients for a period of eight years from 2011-2019. The healing of the lesions was excellent with respect to bone formation, reestablishment of periodontal ligament and reduction in tooth mobility on follow up of six months to one and a half years. This case series gives insight of successful non-surgical management of periapical cysts. We reiterate the effectiveness of non-surgical management of periapical cysts as it was well observed in our case series. The promising prognosis of non-surgical management of periapical cysts can render the surgical options antediluvian.

**Key words:** Periapical cyst; radicular cyst; bay cyst; odontogenic cyst; true cyst

### Access this article online

#### Website:

<http://nepjol.info/index.php/AJMS>

DOI: 10.3126/ajms.v12i6.34051

E-ISSN: 2091-0576

P-ISSN: 2467-9100

Copyright (c) 2021 Asian Journal of Medical Sciences



This work is licensed under a Creative Commons Attribution-NonCommercial 4.0 International License.

## INTRODUCTION

Periapical lesions are the host response to endodontic infections caused by dental caries. Periapical lesions are abscess, granulomas or cysts. The cysts are of two categories: the bay cysts or pocket cysts and the true cysts. Bay cysts are those in continuation with the root canal and true cysts are usually detached from the root canal.<sup>1</sup> These periapical cyst do not resolve with chemo mechanical preparation of the root canal alone. It should be combined with repeated long term intra canal dressing or surgical procedures. Large Periapical cysts managed with surgical therapy poses threat to adjacent normal tooth and their periodontium. Intra canal medication with Ca(OH)<sub>2</sub> and Iodoform (Metapex) is a novel method of treating periapical cysts.

## PATIENTS AND METHODS

Patients with pain in the anterior teeth with clinical finding of trauma or carious lesions were subjected to radiographs. The differential diagnosis of these lesions is impossible without a histopathological examination. However radiological and clinical criteria for diagnosis of periapical cysts are presence of a non-vital tooth, presence of a radiolucency of >5mm, a well-defined radiolucency with a radiopaque border involving one or more tooth and the presence of straw colored fluid on aspiration or from the root canal.<sup>2</sup>

The periapical radiographs were carefully analyzed depending on the radiological criteria for diagnosis of

### Address for Correspondence:

Dr. Bhavanirekha Natarajan, 1/403, Kaveri Main Road, Iyer Bungalow, Madurai-17, India. **Mobile:** +91-6380244036.

**E-mail:** dr.bhavanirekha@gmail.com

periapical cysts. Fifteen patients having all four criteria were taken up for the non- surgical management.

RC opened and straw colored fluid aspirated either from the root canal or from the cyst. Diagnosis of periapical cyst was confirmed. One precaution that was followed on aspiration of the fluid from the canal or from the cysts was the constant digital pressure over the cyst to avoid air entrapment. Diagnostic x-ray made (Figure-1). Length determined (Figure-2) and metapex paste placed in the root canal. Check x-ray showed extension of metapex paste into the cyst in five of our cases (Figure 3 and 4). The canal dressing changed every eight weeks and finally RCT completed after 6 months to one year depending on the size of the cysts and bone formation. The patients were followed up for the assessment of new bone formation in the lesion, period elapsed for healing, reduction in tooth mobility and reestablishment of periodontal ligament. Follow up radiographs, IOPA or occlusal view was taken every 3 months. At the end of six months (smaller cysts) or one and a half years (larger cysts), we found trabecular bone formation and resorption of extended paste in the cystic cavity (Figure 5). During the entire procedure no flare ups were seen. The healing of Periapical lesion is quite evident as the cystic cavity was being filled with bone.

## DISCUSSION

Non-surgical management of these cysts should be adopted before advising surgery. The non-surgical treatments options are long term repeated intra canal dressing, aspiration and drainage through root canal, aspiration and decompression technique.

Repeated intra canal dressing is the most popular technique and we adopted intra canal dressing with Metapex paste. Metapex paste has calcium hydroxide, Iodoform, 38% (antibacterial), silicone oil vehicle and barium sulphate (radiopaque material).The non-water silicone oil vehicle promotes low solubility and slow diffusion of calcium hydroxide in the tissues.

The Periapical region has rich blood supply, lymphatic drainage and undifferentiated cells. The periapical cysts do not respond to conventional RCT alone. Most often after RCT patient develop persistent swelling, sinus tracts and recurrent infections. A non-vital tooth with a carious lesion leads to the formation of granulomas, Bay Cysts and true cysts. Bay Cysts have epithelium in continuation with the root canal system and true cysts develop as a self-perpetuating entity and do not respond to non-surgical management.<sup>3</sup> Lin et al.,<sup>4</sup> suggested treatment of any periapical lesion with a conservative non-surgical

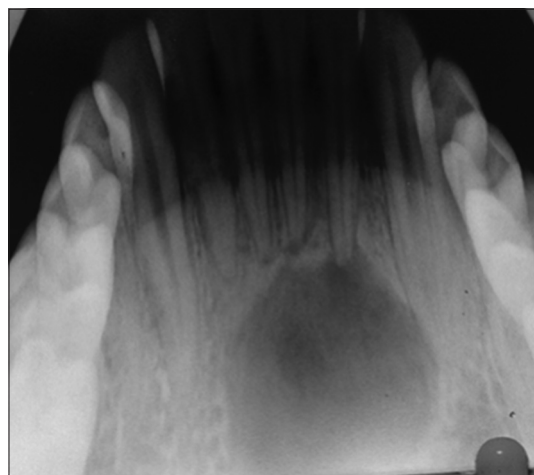


Figure 1: Pre-operative image

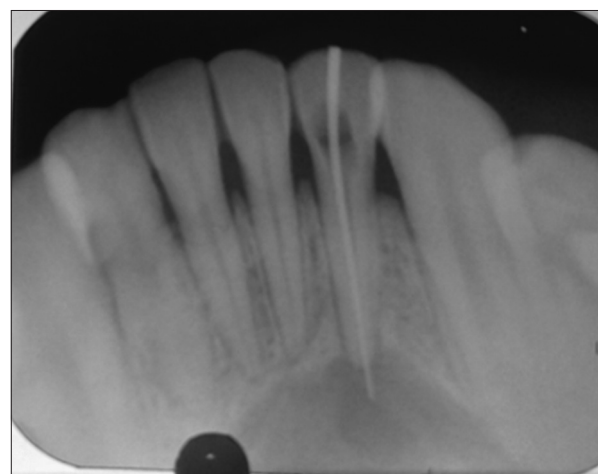


Figure 2: Diagnostic radiograph

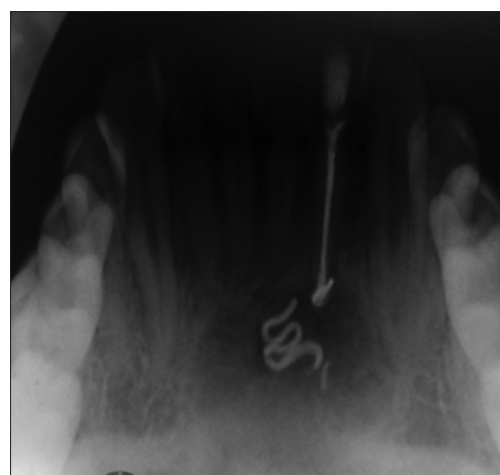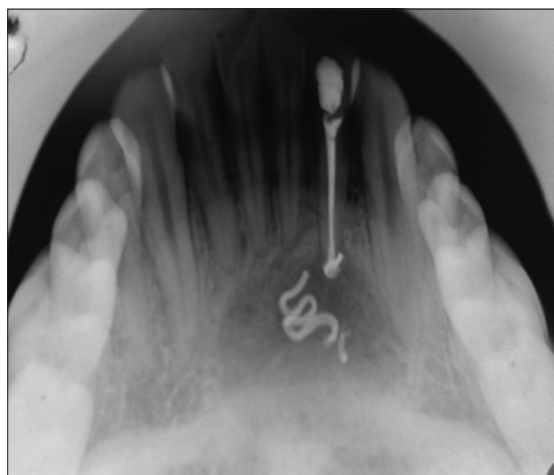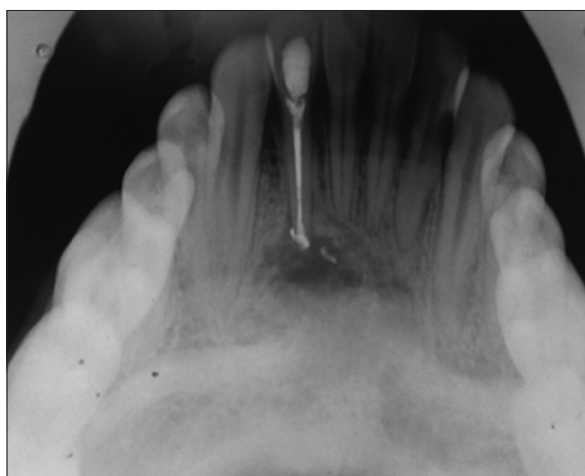


Figure 3: With metapex paste

management as a first priority. Microorganisms in the necrotic pulp release toxins into the periapical tissues at the interface between the apex and the periodontal tissues. The inflammatory process contributes to the formation



**Figure 4:** Bone formation



**Figure 5:** Healing of the cyst and resorption of the paste

of periapical lesion.<sup>5</sup> The growth of the cyst is due to increase in hydrostatic pressure which enhances osteoclastic activity.<sup>6</sup>

Since the introduction of  $\text{Ca}(\text{OH})_2$  in 1920, it is the most popular and time tested intra canal medicament. It has a pH of 2.5 and diffuses into calcium and hydroxyl ions. This hydroxyl ion is an oxidant free radical and exerts microbicidal activity by disruption and damage to DNA, cell membrane, protein denaturation and nullifying the effect of bacterial endotoxins.<sup>7</sup> The Oxidant free radical is also responsible for the inhibition of tooth resorption and tissue resolving ability.<sup>8-10</sup>

Negri *et al.*, claimed that intra canal medicaments can only be used as an adjuvant for cleaning and shaping and should not to be used as an alternative.<sup>11</sup> The increase in hydrostatic pressure of the cyst leads to increase osteoclastic activity<sup>12</sup> and aspiration and decompression of the cysts is of paramount importance in reducing this osteoclastic activity. Approximately 70% of cases with periapical lesions heal

in two years of treatment.<sup>13</sup> Increase in instrumentation 1mm beyond the apex leads to pressure release and strangulation of cyst. This leads to conversion of a cyst to granulomas and it gradually heals.<sup>14-16</sup> A large peri radicular lesion may have a direct communication with the root canal system (apical pocket cyst) and responds favorably to nonsurgical treatment. Clinical studies have confirmed that simple nonsurgical treatment with proper infection control can promote healing of large lesions. When this treatment is not successful in resolving the periradicular pathosis, additional treatment options such as marsupialization or tube decompression should be considered.<sup>17-21</sup>

In our institutional experience, we found that the large periapical cysts respond well to root canal therapy combined with repeated Metapex paste dressing. It is well documented worldwide that healing of those periapical lesions is excellent with this modality of treatment.

## CONCLUSION

RCT combined with repeated intra canal dressing obviate the need for surgery in most of the similar clinical scenarios. Surgical treatment should be reserved for non-responding cases and in cases of true cysts in lieu of its complications.

## REFERENCES

1. Simon JHS, Enciso R, Malfaz JM, Roges R, Perry MB and Patel A. Differential diagnosis of large periapical lesions using cone-beam computed tomography measurements and biopsy. *JOE* 2006; 32(9):833-837.  
<https://doi.org/10.1016/j.joen.2006.03.008>
2. Natkin E, Oswald RJ and Carnes LI. The relationship of lesion size to diagnosis, incidence and treatment of periapical cysts and granulomas. *Oral Surg Oral Med Oral Pathol.* 1984; 57(1):82-94.  
[https://doi.org/10.1016/0030-4220\(84\)90267-6](https://doi.org/10.1016/0030-4220(84)90267-6)
3. Eversole LR (1984). *Clinical outline of oral pathology: diagnosis and treatment*, 2nd edn. Philadelphia: Lea & Febiger: 203-259.
4. Lin LM, Huang GTJ and Rosenberg PA. Proliferation of epithelial cell rests, formation of apical cysts, and regression of apical cysts after periapical wound healing. *Journal of Endodontics.* 2007; 33: 908-916.  
<https://doi.org/10.1016/j.joen.2007.02.006>
5. Kandari AM, Quoud OA and Gnansekhar JD. Healing of large periapical lesions following non surgically endodontic therapy: case reports. *Quintessences International.* 1994; 25(2):115-119.
6. Toller PA. Newer concepts of odontogenic cysts. *Int J Oral Surg.* 1972; 1(1):3-16.  
[https://doi.org/10.1016/S0300-9785\(72\)80031-0](https://doi.org/10.1016/S0300-9785(72)80031-0)
7. Abu Zeid ST. Non surgical management of periapical pathosis associated with sinus tract in one appointment using calcium hydroxide based root canal sealer. *Al Azhar Dent J.* 1992; 7:321-333.
8. Heithersay GS. Calcium hydroxide in treatment of pulpless teeth with associated pathology. *J Br Endodon Soc.* 1975; 8: 74-93.  
<https://doi.org/10.1111/j.1365-2591.1975.tb01000.x>
9. Soares JA, Leonardo MR, da Silva LA, Tanomaru Filho M and

- Ito IY. Effect of rotary instrumentation and of the association of calcium hydroxide and chlorhexidine on the antiseptics of the root canal system in dogs. *Brazil Oral Res.* 2006; 20: 120-126.  
<https://doi.org/10.1590/S1806-83242006000200006>
10. Mori GG, Ferreira FC, Batista FRS, Godoy MAS and Nunes DC. Evaluation of the diffusion capacity of calcium hydroxide pastes through the dentinal tubules. *Brazil Oral Res.* 2009; 2: 113-118.  
<https://doi.org/10.1590/S1806-83242009000200004>
  11. Negri MR, Panzarini SR, Poi WR, Sonoda CK, Gulinelli JL and Saito CTMH. Analysis of the healing process in delayed tooth replantation after root canal filling with calcium hydroxide, Sealapex and Endofill: a microscopic study in rats. *Dent Traumatol.* 2006; 2:645-650.  
<https://doi.org/10.1111/j.1600-9657.2008.00682.x>
  12. de la Casa ML, Salas MM, Lópes ME and Raiden G. Protein content in irrigation solutions in contact with pulp tissue. *Acta Odontol Latinoam.* 2008; 21: 65-68.
  13. Walton RE. Intracanal medicaments. *Dental clinics of North America.* 1984; 28: 783-796.
  14. Toller PA. Newer concepts of odontogenic cysts. *Int J Oral Surg.* 1972; 1(1):3-16.  
[https://doi.org/10.1016/S0300-9785\(72\)80031-0](https://doi.org/10.1016/S0300-9785(72)80031-0)
  15. Caliskan MK. Prognosis of large cyst-like periapical lesions following nonsurgical root canal treatment: a clinical review. *Int Endod J.* 2004; 37(6):408-416.  
<https://doi.org/10.1111/j.1365-2591.2004.00809.x>
  16. Bhaskar SN. Periapical lesions-types, incidence, and clinical features. *Oral Surg Oral Med Oral Pathol.* 1996; 21:657-671.  
[https://doi.org/10.1016/0030-4220\(66\)90044-2](https://doi.org/10.1016/0030-4220(66)90044-2)
  17. Cwikla SJ, Bélanger M, Giguère S and Fox AP. Dentinal tubule disinfection using three calcium hydroxide formulations. *J Endod.* 2005; 31(1): 50-52.  
<https://doi.org/10.1097/01.DON.0000134291.03828.D1>
  18. Fava LR and Saunders WP. Calcium hydroxide pastes: classification and clinical indications. *Int Endod J.* 1999;32(4):257-282.  
<https://doi.org/10.1046/j.1365-2591.1999.00232.x>
  19. Pacios MG, de la Casa ML, de los Angeles Bulacio M and Lopez ME. Calcium hydroxide's association with different vehicles: in vitro action on some dentinal components. *Oral Surg Oral Med Oral Pathol Oral Radiol Endod.* 2003; 96(1):96-101.  
[https://doi.org/10.1016/S1079-2104\(02\)91705-1](https://doi.org/10.1016/S1079-2104(02)91705-1)
  20. Soares JA, Leonardo MR, Tanomaru Filho M, Silva LAB and Ito IY. Effect of biomechanical preparation and calcium hydroxide pastes on the anti-sepsis of root canal systems in dogs. *J Appl Oral Sci.* 2005; 13(1):93-100.  
<https://doi.org/10.1590/S1678-77572005000100019>
  21. Fernandes M and Ataíde I. Non-surgical management of a large periapical lesion using a simple aspiration technique: a case report. *Int Endod J.* 2010;43(6):536-542.  
<https://doi.org/10.1111/j.1365-2591.2010.01719.x>

**Author's contribution:**

**DK-** Conception and design of the work and reviewed the literature and final approval of the version to be published; **VP-** Manuscript preparation and Critical revision of the article; **NB-** Data collection, manuscript preparation; **BR-** reviewed the literature and final approval of the version to be published **ND-** Design of the study and critical revision of the article.

**Work attributed to:**

Department of Dentistry, Indira Gandhi Medical College and Research Institute (Government), Puducherry-605008, India.

**Orcid ID:**

Dr. Devakumari- <https://orcid.org/0000-0001-9166-2285>  
 Dr. Vijhayapriya- <https://orcid.org/0000-0001-7570-3497>  
 Dr. Nandini Biradar- <https://orcid.org/0000-0003-4885-6898>  
 Dr. Bhavani Rekha- <https://orcid.org/0000-0002-7644-2361>  
 Dr. Neil Dominic- <https://orcid.org/0000-0003-1505-7117>

**Source of Funding:** None, **Conflict of Interest:** None.